



**PATIENT**

Teddy Kohe

**SPECIES**

Canine

**BREED**

Poodle Mix

**SEX**

Male Neutered

**AGE**

11.9 years

**WEIGHT**

49.8lbs

**INTERPRETED BY**

Maggie Machen Lamy,  
DVM, DACVIM  
(Cardiology)

**IMAGING PERFORMED BY**

Greg Kuhlman, DVM

**HOSPITAL NAME**

Red River Animal  
Emergency Hospital &  
Referral Center

**REFERRING VET**

Dr. Kuhlman

**INVOICE**

46750

**DATE**

2/9/26

**PRESENTING CLINICAL SIGNS**

History: Intermittent heart murmur (not heard today). Dry intermittent cough; worse at night. CXR (1/14/26) showed mild cardiomegaly, no CHF. Prominent MPA and a redundant dorsal tracheal membrane. Started on Hydrocodone. Sedated with Gabapentin.

**ECHOCARDIOGRAM FINDINGS**

2D, m-mode, color flow and doppler imaging is available. Diffuse thickening of mitral valve leaflets with prolapse into the left atrial lumen. Severe eccentric mitral regurgitation with severe left atrial dilation. LV dilation with hyperdynamic myocardial function. The tricuspid valve appears mildly thickened with mild tricuspid regurgitation. TR velocity is normal. Right heart is mildly dilated. The pulmonic and aortic valves are normal in morphology and mobility. Normal pulmonic and aortic outflow velocities. No aortic or pulmonic insufficiency. No pericardial or pleural effusion noted. No obvious cardiac tumors observed.

**CARDIAC CHART**

CANINE CARDIAC PARAMETERS	MR VMAX (m/s)	TR VMAX (m/s)	LA/AO (Boon method)	LA/AO (Heart Base; Swe)	FS (%)	EF (%)	EPSS (cm)
<b>NORMAL PARAMETER</b>	4.5-5.5	<2.7	1.3	<1.6	28-40	40-100	<0.6
<b>PATIENT</b>	5.0	2.2	NM	NM	38	70	NM
CANINE CARDIAC PARAMETERS	HR (BPM)	AV VMAX (m/s)	PV MAX (m/s)	BODY WEIGHT (kg)	LA 2D short axis Base view (cm)	LVIDd Avg; 2D and m-mode short axis (cm)	LVIDs Avg; 2D and m-mode short axis (cm)
<b>NORMAL PARAMETER</b>	50-100	0.7-1.7	0.7-1.6	BELOW	BELOW	BELOW	BELOW
<b>PATIENT</b>	NM	0.8	0.9	22.6	est >2.0	4.1	2.5
*Normal chamber parameters expressed as a mean value (SD)				3	1.27 (5.3)	2.46 (2.46)	1.36 (5.5)
<b>BODY WEIGHT DEPENDENT PARAMETERS</b>				5	1.40 (4.5)	2.74 (5.2)	1.60 (4.7)
<i>*Note: All measurements based upon multi-modal images and methods. An average value is reported.</i>				10	1.50 (3.8)	3.27 (3.5)	2.06 (3.1)
				15	1.83 (2.0)	3.71 (2.4)	2.43 (2.1)
				20	2.02 (1.9)	4.14 (2.2)	2.80 (2.0)
				25	2.18 (2.4)	4.48 (2.9)	3.10 (2.5)
				30	2.33 (3.3)	4.83 (3.9)	3.39 (3.4)
				35	2.48 (4.3)	5.17 (5.0)	3.69 (4.5)
				40	2.62 (5.2)	5.48 (6.1)	3.96 (5.4)
				50	2.88 (7.1)	6.07 (8.3)	4.46 (7.4)

**INTERPRETATION OF THE FINDINGS & FURTHER RECOMMENDATIONS**

Chronic degenerative valve disease causing severe mitral and mild tricuspid regurgitation. Significant left atrial and ventricular enlargement indicate the risk for spontaneous congestive heart failure is elevated. No obvious additional issues are noted.

A cough in this patient with severe heart disease is likely multi-factorial in origin, including mainstem bronchi compression and/or potentially some degree of upper or lower airway disease. Early CHF/pulmonary edema should also be considered; however, this is less likely based



**PATIENT**

Teddy Kohe

**SPECIES**

Canine

**BREED**

Poodle Mix

**SEX**

Male Neutered

**AGE**

11.9 years

**WEIGHT**

49.8lbs

**INTERPRETED BY**

Maggie Machen Lamy,  
DVM, DACVIM  
(Cardiology)

**IMAGING PERFORMED BY**

Greg Kuhlman, DVM

**HOSPITAL NAME**

Red River Animal  
Emergency Hospital &  
Referral Center

**REFERRING VET**

Dr. Kuhlman

**INVOICE**

46750

**DATE**

2/9/26

upon the CXR results as well as a reported cough in the absence of labored breathing. Recommend institute cardiac supportive medications including a weak diuretic (spironolactone) for potential survival benefit and advise close monitoring at home for need for Lasix therapy. Cough suppression (up to q4-6 hours) may also be helpful for any component of a mechanical cough. **Monitoring of sleeping breathing rates is recommended as the best way to screen for CHF at home.**

Omega fatty acid supplementation and mild salt restriction may also be of some long-term benefit. Monitor for development of a worsening cough, labored breathing, exercise intolerance or collapse episodes. Long term prognosis is guarded to poor with stage (late) B2 disease, with risk for CHF in the near future. Once diagnosed, the average survival time for canine patients is 8-9 months on medications; however, most are able to maintain a good quality of life for that period. Patient will always be at risk for progression to CHF, development of arrhythmias/LA tear, syncope and/or sudden death in the future.

**Elective anesthesia is not advised, as there is high risk for complication.** Risk: benefit ratio should be considered. Consider consultation with and/or referral to a facility with an anesthesiologist. Should you elect to proceed, cardiac protective drug choices (opioid/benzodiazepine premedication, propofol or alfaxalone induction, iso or sevoflurane gas) are recommended. Pre-oxygenate for 5-10 minutes prior to induction and recover in O2 cage. Monitor for arrhythmias, hypotension, and hypoxia both intra and post-operatively and intervene as necessary. Moderate IV fluid restriction is recommended to avoid fluid overload, while considering comorbidities, hydration status, BP, etc. Avoid heart rate stimulating drugs such as atropine unless clinically indicated.

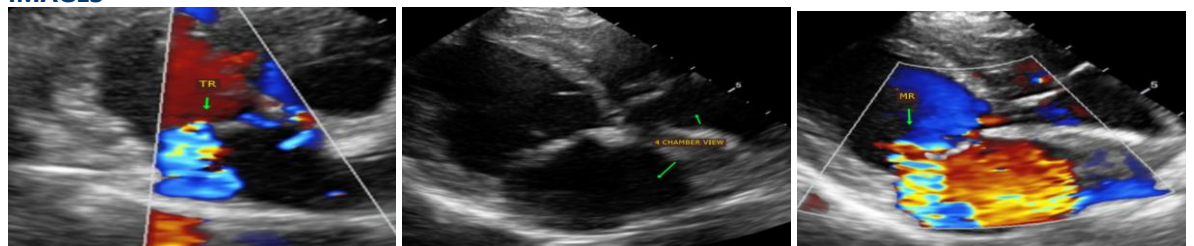
**PLAN**

Baseline BP recommended. Institute Pimobendan 0.3mg/kg PO q12h. Institute Spironolactone 1-2mg/kg PO q12h. If BP > 130mmHg, institute ACE-I (benazepril or enalapril) 0.5mg/kg PO q12h. Consider hydrocodone with homatropine for QOL (0.2-0.4mg/kg PO up to q4-6 hours PRN for cough; available in 5/1.5mg tabs and 5mg/5ml liquid suspension).

A renal panel and BP are recommended in 1-2 weeks, then every 3-4 months lifelong to ensure tolerance of medications.

A recheck echocardiogram is recommended in 6 months to screen for progression, sooner if clinical signs arise in the interim.

**IMAGES**





## PATIENT

Teddy Kohe

## SPECIES

Canine

## BREED

Poodle Mix

## SEX

Male Neutered

## AGE

11.9 years

## WEIGHT

49.8lbs

## INTERPRETED BY

Maggie Machen Lamy,  
DVM, DACVIM  
(Cardiology)

## IMAGING PERFORMED BY

Greg Kuhlman, DVM

## HOSPITAL NAME

Red River Animal  
Emergency Hospital &  
Referral Center

## REFERRING VET

Dr. Kuhlman

## INVOICE

46750

## DATE

2/9/26

**The information and recommendations provided are based on the images presented by the referring veterinarian. No evaluation can be communicated regarding pathology that was not visible in the image/video clips provided.**

Thank you for this referral. This report was generated using transcription software, and minor dictation errors may be present. If the clinical or image interpretation does not parallel your findings or if I can be of any further assistance, please contact me.

**Maggie Machen Lamy, DVM**

**Diplomate of the American College of Veterinary Internal Medicine (Cardiology)**

info@sonopath.com